

HOSTED BY




ELSEVIER

Available online at [www.sciencedirect.com](http://www.sciencedirect.com)

ScienceDirect

journal homepage: <http://www.elsevier.com/locate/ijpam>



## CASE REPORT

# Tamoxifen to treat male pubertal gynaecomastia



Anthony Zehetner\*

Gosford Paediatrics, Suite 9, 16-18 Hills Street, Gosford, NSW 2250, Australia

Received 18 August 2015; received in revised form 11 September 2015; accepted 16 September 2015  
Available online 23 October 2015

### KEYWORDS

Gynaecomastia;  
Puberty;  
Male;  
Tamoxifen;  
Mastodynia;  
Surgery

**Abstract** Pubertal gynaecomastia affects up to 70% of male adolescents, with the highest prevalence occurring at 14 years of age. While spontaneous regression occurs in 90% of cases within three years, until then, symptoms of mastodynia and psychological distress are prevalent in some patients prior to surgical treatment. Tamoxifen, a selective oestrogen receptor modulator (SERM), given at 20 mg daily for six months, was found to be a safe, well-tolerated and effective alternative treatment to current therapeutic options of watchful waiting (no management) and invasive cosmetic surgery. No adverse effects were observed in hormonal and auxological studies. The patient presented was able to avoid undergoing surgery, which should be reserved for persistent gynaecomastia present at the end of puberty after failing a trial of tamoxifen. Randomised controlled trials (RCTs) are needed for definitive therapeutic recommendations.

Copyright © 2015, King Faisal Specialist Hospital & Research Centre (General Organization), Saudi Arabia. Production and hosting by Elsevier B.V. This is an open access article under the CC BY-NC-ND license (<http://creativecommons.org/licenses/by-nc-nd/4.0/>).

## 1. Introduction

Gynaecomastia of adolescence is a common pubertal occurrence and is often associated with persistent physical discomfort and psychological distress in males. Many treatment options have been proposed, ranging from watchful waiting (no treatment), modification of hormonal

axes using medication and surgical intervention. The following case discussion provides an overview of the condition and describes the successful effect from using a six-month course of tamoxifen, a Selective Oestrogen Receptor Modulator (SERM), to treat pubertal gynaecomastia in a typical teenage male.

## 2. Case report

A 14-year-old boy presented with unilateral left-sided gynaecomastia present for the past twelve months (Fig. 1). There was associated breast pain (mastodynia) of 5/10 severity, which was worse when wearing tight-fitting

\* Tel.: +61 2 4322 5437; fax: +61 2 4322 5436.

E-mail address: [drz@gosfordpaediatrics.com.au](mailto:drz@gosfordpaediatrics.com.au).

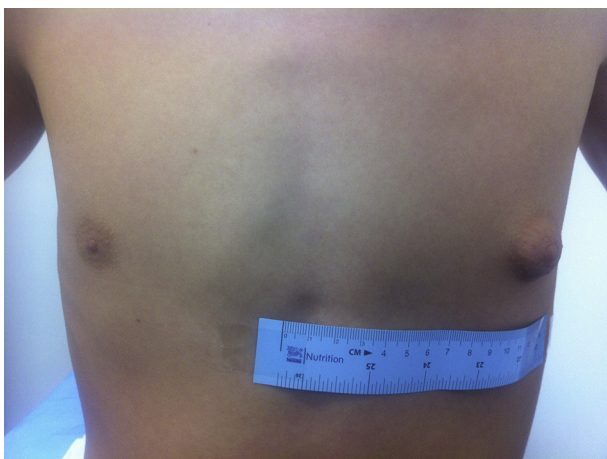Peer review under responsibility of King Faisal Specialist Hospital & Research Centre (General Organization), Saudi Arabia.

shirts. He was a keen swimmer and due to feeling self-conscious and being teased by peers in the locker room had not been attending sports sessions. He had been referred for suction lipectomy (liposuction) and was presented for paediatrician review for possible medical therapy to avoid surgery.

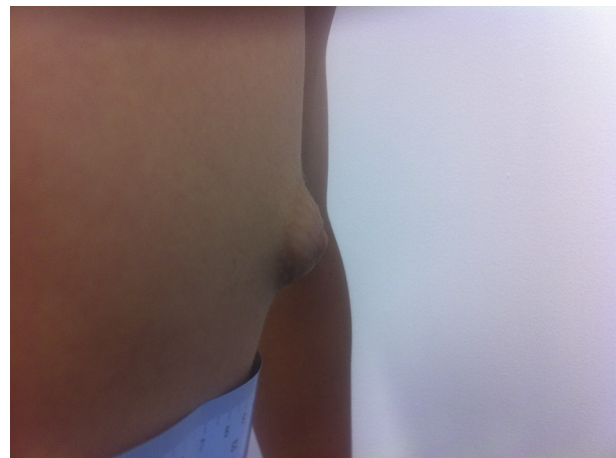The lesion measured 3 cm in diameter with marked prominence (Fig. 2). A tender 'disk' of firm tissue was palpable beneath the areolar region. The boy was not overweight (body mass index (BMI) of 20.2, 60th centile) and was in Tanner Stage 3 puberty (right testicular volume 10 mL, left 15 mL) with normal secondary sexual characteristics for his age. He denied taking any regular medication or having used any illicit substances, such as cannabis. There was a positive family history of pubertal gynaecomastia in his two older brothers, with one having had liposuction performed. Blood tests showed a high normal testosterone level (27 nmol/L), raised sex-hormone binding globulin (SHBG) 93 nmol/L (normal range 15–50 nmol/L) and slightly raised dehydroepiandrosterone sulphate (DHEAS) at 5  $\mu$ mol/L (normal range 0.1–4.2  $\mu$ mol/L). Other indices were normal; including a free androgen index (FAI) of 29%; oestradiol: <50 pmol/L; prolactin: 305 mIU/L; quantitative beta-human chorionic gonadotropin ( $\beta$ -hCG): <5 IU/L; follicle stimulating hormone (FSH): 1.7 IU/L; luteinising hormone (LH): 2.0 IU/L; and a full blood count, electrolytes and karyotype (46 XY), excluding Klinefelter Syndrome.

### 3. Discussion

Pubertal gynaecomastia is a benign physiological process arising from a transient imbalance between the greater stimulatory effects of oestrogens and lesser inhibitory effects of androgens on breast tissue during puberty. It is usually bilateral and affects up to 70% of adolescent males [1], with a peak incidence at approximately 14 years of age [2]. Oestrogen levels may become elevated from increased peripheral aromatase activity (often occurring in the adipose tissue of obese males and delaying puberty). This increases the SHBG levels, which bind free (active) testosterone, reducing its antitrophic action on breast tissue. Glandular proliferation, ductal hyperplasia and



**Figure 1** Prominent unilateral pubertal gynaecomastia at baseline. Left breast measures 3 cm [2].



**Figure 2** Side view of prominent left unilateral pubertal gynaecomastia at baseline.

periductal inflammation occur as a result. This rapid growth often occurs over the first six months of Tanner Stage 3 puberty, when pubertal gynaecomastia is most symptomatic (enlargement, pain and tenderness). While pubertal gynaecomastia is a cosmetic condition and the natural history is spontaneous regression in 90% of cases within three years [3], it is frequently psychologically distressing and causes embarrassment until it does so, with some adolescents electing to undergo potentially disfiguring surgery [4].

Gynaecomastia is clinically defined by the presence of a rubbery-to-firm disk-like mass that is often mobile, located directly inferior to the areolar region and extending concentrically from the nipple. It is distinct from pseudo-gynaecomastia (or lipomastia), which is an adipose tissue deposition without glandular proliferation, where no firm mass is palpable. Histological examination of mastectomy samples taken from males under 21 years of age for adolescent gynaecomastia show the incidence of breast cancer being extremely low [5]. The malignant lesion invariably involves the unilateral breast; is often hard, fixed and, eccentric; and may be associated with spontaneous bloody nipple discharge, axillary lymphadenopathy or overlying skin discolouration, dimpling or tethering (*peau d'orange*). A family history of gynaecomastia is reported in approximately 60% of cases [2]. The contributing factors for gynaecomastia need to be considered. These include hypogonadism, medication (notably antipsychotics, including the newer atypical agents, such as risperidone, as well as other drugs, for instance, spironolactone), alcohol, marijuana or anabolic steroid use. In such cases, the precipitating cause should be attended to first.

Three management options are available: (i) reassurance (i.e., no treatment), (ii) surgery and (iii) medication. The first is the safest option, although does not ameliorate symptoms and is best for small, pain-free cases of recent onset (<6 months). Surgery is usually a combination of direct excision of the glandular tissue and liposuction. Performing surgery is recommended after adult testicular size (Tanner Stage 5 puberty) is attained, as there may be regrowth of the breast tissue if performed earlier. Surgery may also involve complications, such as scarring, skin retraction and hyperaesthesia. Thus, it should be reserved

for persistent cases, large and pendulous breasts unresponsive to medical therapy, removing redundant tissue or if significant fibrosis is present [6].

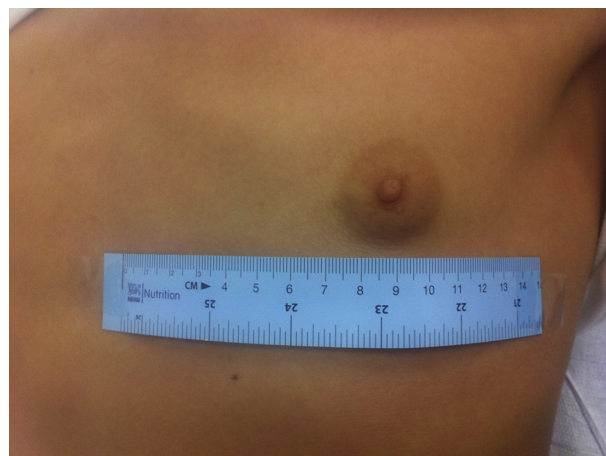
Medications aim to increase the effective androgen/oestrogen imbalance and fall into three classes: (i) selective oestrogen receptor modulators, SERMs (tamoxifen and raloxifene); (ii) aromatase inhibitors (anastrozole); and (iii) androgens (for hypogonadism). Aromatase inhibitors block the biosynthesis of oestrogen and have inferior results compared to SERMs in clinical studies of the treatment of pubertal gynaecomastia. SERMs block the growth-stimulating effects of oestrogen on breast tissue, although they are oestrogenic elsewhere in the body (bone and adipose tissues).

There have been no randomised controlled trials (RCTs) of SERMs for the treatment of pubertal gynaecomastia, and the medications are not registered for this indication in Australia. While RCTs exist for the use of tamoxifen in anti-androgen-induced gynaecomastia in adults treated for prostatic cancer [7], it may be difficult to extrapolate the clinical effect between these patient populations, although the theoretical role of tamoxifen is sound. A recent systematic review of tamoxifen therapy for the management of pubertal gynaecomastia [8] found it to be a safe and effective medical option. Doses of 10–40 mg of tamoxifen per day were used in adolescent males under the age of twenty for 1–12 months, with the resolution of mastodynia and  $\geq 80\%$  reduction in swelling noted. The response was dependent on the length of therapy, and recurrence of gynaecomastia occurred in up to 14% of cases after therapy cessation. SERMs appear to be most effective within the first 6 months of gynaecomastia when the breast tissue growth is most abundant and before fibrosis occurs.

One observational study [2] has shown that tamoxifen administered at a dose of 20 mg per day (as a single or divided dose) for three months was a safe option in treating pubertal gynaecomastia. Significant regression occurred in approximately 90% of teenage boys, involving a mean reduction in the breast nodule diameter of 2.1 cm (almost half of the baseline diameter). Individuals with a smaller breast diameter at baseline had a better outcome. Mastodynia was also reduced. The same study found similar and slightly superior results with a different SERM, raloxifene. However, as there is even less experience and available data regarding the use of raloxifene for the treatment of pubertal gynaecomastia than with tamoxifen; its current use in clinical practice is limited.

Importantly, no clinically significant side-effects, changes in the gonadotrophin levels or height during treatment have been reported. Tamoxifen was well-tolerated in the doses and duration used to treat pubertal gynaecomastia in males [9]. While adverse events are rare, tamoxifen use should be avoided in individuals with known risk factors for venous thromboembolism and in the very sedentary, as the potential for deep vein thrombosis (DVT) exists. Any mood changes and leg cramps should be investigated. Occasional nausea and headaches may be expected.

Breast tissue was found to regress spontaneously in up to half of cases in trial control groups, so tamoxifen should be used judiciously. Recurrence of gynaecomastia may occur



**Figure 3** After 6 months of tamoxifen treatment. The left breast now measures 2 cm [2] (33% reduction).

in up to 25% cases after tamoxifen is ceased, so a further course for six months may be indicated, as well as for non-responders [2]. However, fewer individuals treated with tamoxifen went on to have breast surgery, so its role in surgery prevention is pivotal.

The boy in the case study was treated with tamoxifen, 20 mg per day, for six months. Within the first few weeks, the patient's mastodynia completely resolved and he noticed that his left gynaecomastia began to reduce in size. After three months, his body image satisfaction improved and he resumed participation in sports involving being bare-chested and changing in front of his peers. After six months, the residual left breast was 2 cm in diameter (33% reduction from baseline), flatter, without any palpable underlying firm tissue and was symmetrical in size to the other breast (Fig. 3). The boy did not report any adverse effects while being treated with tamoxifen, consistent with the published reports. Auxological parameters, including anthropometry, growth velocity, progress pubertal staging, bone age X-ray and repeat hormonal studies, were found to be similar to the baseline values at the conclusion of treatment (the testosterone level was 23.7 nmol/L; the SHBG was 75 nmol/L, which was still elevated though less than previously and could possibly indicate treatment resistance and/or gynaecomastia recurrence on tamoxifen cessation; the DHEAS was 5.6  $\mu\text{mol/L}$ ; the FAI was 31.6%; the FSH was 1.1 IU/L; the LH was 1.9 IU/L; and the oestradiol value was 70 pmol/L). This confirmed that tamoxifen therapy did not adversely affect the hypogonadal pituitary axis in this patient.

This case study demonstrates tamoxifen to be a safe, well-tolerated and effective treatment option for male pubertal gynaecomastia. It resolved mastodynia and quickly reduced psychological distress by acting on the cause of male pubertal gynaecomastia (blocking the action of oestrogen-induced breast tissue proliferation). Tamoxifen treatment was more effective than previous months of watchful waiting (no management). It was also a less invasive treatment approach and reduced the need for planned cosmetic surgery. An even greater effect of tamoxifen therapy may have been observed if the patient had received medical treatment earlier.

Tamoxifen may be effective for the treatment of pubertal gynaecomastia, and it seems to be safe according to the many similar case reports. However, we need evidence from randomised controlled trials (RCTs) to confirm these findings. Until such results are known, tamoxifen should be used on a judicial basis in carefully selected adolescent males with pubertal gynaecomastia causing significant symptoms (both physical and psychological), who are fully informed of the risks and potential benefits (from available studies) and who are considering surgical reduction procedures.

## Conflict of interest

None.

## Appendix

### Key learning points

- Pubertal gynaecomastia affects up to 70% of male adolescents, peaking at 14 years of age
- Medication, drugs (e.g., cannabis), hypogonadism and obesity are causative differential diagnoses
- Tamoxifen, a selective oestrogen receptor modulator (SERM), appears to be a safe and effective alternative treatment option in adolescent males with significant symptoms considering surgery
- Randomised controlled trials (RCTs) are needed for definitive therapeutic recommendations
- Surgery/liposuction should be reserved for persistent cases present at the end of puberty

## Multiple choice questions

1. Which individual is at the greatest risk of developing pubertal gynaecomastia?

- An overweight 7-year-old boy whose father has prostate cancer
- A 12-year-old boy with growing pains from a recent growth spurt who is medicated with olanzapine
- A 17-year-old male who smokes 1 g of cannabis daily
- A 13-year-old boy with XYY Syndrome and significant facial acne
- A 16-year-old boy on androgen replacement therapy that shaves and has one alcoholic drink monthly at parties

**Answer: (b)**

- An overweight child may exhibit pseudogynaecomastia (or lipomastia) as an adolescent. Gynaecomastia occurs in 10–20% of men treated with LHRH agonists for prostate cancer, although this factor would not affect the son.
- Increased growth velocity in boys usually occurs at the onset of Tanner Stage 3 when pubertal gynaecomastia also occurs. Antipsychotic medication, including the newer second-generation atypical agents, block dopamine and induce hyperprolactinaemia, causing gynaecomastia and/or**

**galactorrhoea, with risperidone being the most frequently implicated medication.**

- Pubertal gynaecomastia is uncommon in males over 17 years of age. Cannabis use has less effect on gynaecomastia once puberty is completed, although it may still have a deleterious effect on testosterone levels and spermatogenesis.
- Boys with XYY Syndrome rarely have hypogonadism and display gynaecomastia. This is more commonly seen in Klinefelter syndrome (XXY). Significant facial acne indicates virilisation and makes hypogonadism less likely.
- A virilised adolescent male in mid-to-late puberty on appropriate androgen replacement is unlikely to have hypogonadism, as well as pubertal gynaecomastia, based on age. Chronic alcohol use may reduce testosterone levels and induce gynaecomastia, although this would not occur with mild, infrequent use.

2. Which one of the following statements best describes a typical clinical presentation of pubertal gynaecomastia on palpation?

- A unilateral painful hard mass with axillary lymphadenopathy
- Bilateral mobile and tender disc-like mounds of tissue just beneath the nipple–areolar complex
- A mass associated with nipple discharge
- Multiple fixed peripheral masses with overlying skin discolouration
- A dimpled appearance to the breast similar to an orange peel

**Answer: (b)**

Pubertal gynaecomastia is often bilateral with the proliferated breast tissue palpable, as described in answer (b). Any lesion which is fixed, hard, peripherally located and/or associated with lymphadenopathy (a), discharge (c), skin discolouration (d) or tethering (peau d'orange in answer (e)) should raise the suspicion of breast cancer (invariably unilateral), and the patient should be referred for mammography.

3. Which one of the following statements best describes treatment for pubertal gynaecomastia?

- Liposuction should be performed as early as possible
- Tamoxifen is effective, but produces serious adverse effects
- Anastrozole is a superior medical therapy compared to tamoxifen
- Tamoxifen may reduce the incidence of patients undergoing gynaecomastia surgery
- Pharmacotherapy is most effective when instituted after 12 months of watchful waiting

**Answer: (d)**

- Suction lipectomy (liposuction) should be performed when puberty has been completed (Tanner Stage 5) as there is a risk of gynaecomastia recurrence and complication. As 90% of pubertal gynaecomastia will resolve within three years, surgery should be reserved for persistent cases, large and pendulous breasts unresponsive to medical therapy, for removing redundant tissue or if a high degree of fibrosis is present.

- (b) In multiple studies using low doses and short treatment courses for pubertal gynaecomastia, tamoxifen has been well-tolerated without significant side effects. Headache and nausea may be reported. A potential risk of deep vein thrombosis (DVT) would preclude its use in sedentary individuals or those at an increased risk of venous thrombosis. This has not been reported in the generally fit and active adolescents it has been used in to date, who are at very low cardiovascular risk. Any mood changes and leg cramps should be investigated, as with adults taking tamoxifen.
- (c) Aromatase inhibitors block the biosynthesis of oestrogen from testosterone and have been shown to be inferior to Selective Oestrogen Receptor Modulators (SERMs), such as tamoxifen, in clinical trials to treat gynaecomastia.
- (d) **By reducing breast size and pain over the long term in 75% cases, patients treated with tamoxifen have less need to undergo surgery for pubertal gynaecomastia.**
- (e) Watchful waiting is best for small, pain-free cases of pubertal gynaecomastia of recent onset (<6 months). Breast tissue growth is most abundant within the first six months, and most symptoms occur during this time. Medical therapy has the greatest effect when initiated on large, painful lesions before six months have elapsed. After 12 months, there is a higher chance of breast tissue fibrosis and less response to medical therapy.

## References

- [1] Bell DL, Breland DJ, Ott MA. Adolescent and young adult male health: a review. *Pediatrics* 2013 Sep;132(3):535–46. <http://dx.doi.org/10.1542/peds.2012-3414>. Epub 2013 Aug 12.
- [2] Lawrence SE, Faught KA, Vethamuthu J, Lawson ML. Beneficial effects of raloxifene and tamoxifen in the treatment of pubertal gynecomastia. *J Pediatr* 2004 Jul;145(1):71–6. <http://dx.doi.org/10.1016/j.jpeds.2004.03.057>.
- [3] Khan HN, Blamey RW. Endocrine treatment of physiological gynaecomastia. *BMJ* 2003 Aug 9;327(7410):301–2. <http://dx.doi.org/10.1136/bmj.327.7410.301>.
- [4] Lemaine V, Cayci C, Simmons PS, Petty P. Gynecomastia in adolescent males. *Semin Plast Surg* 2013;27(1):56–61. <http://dx.doi.org/10.1055/s-0033-1347166>.
- [5] Koshy JC, Goldberg JS, Wolfswinkel EM, Ge Y, Heller L. Breast cancer incidence in adolescent males undergoing subcutaneous mastectomy for gynecomastia: is pathologic examination justified? A retrospective and literature review. *Plast Reconstr Surg* 2011 Jan;127(1):1–7. <http://dx.doi.org/10.1097/PRS.0b013e3181f9581c>.
- [6] Cuhaci N, Polat SB, Evranos B, Ersoy R, Cakir B. Gynecomastia: clinical evaluation and management. *Indian J Endocrinol Metab* 2014 Mar;18(2):150–8. <http://dx.doi.org/10.4103/2230-8210.129104>.
- [7] Kunath F, Keck B, Antes G, Wullich B, Meerpohl JJ. Tamoxifen for the management of breast events induced by non-steroidal antiandrogens in patients with prostate cancer: a systematic review. *BMC Med* 2012;10:96. <http://dx.doi.org/10.1186/1741-7015-10-96>.
- [8] Lapid O, van Wingerden JJ, Perlemuter L. Tamoxifen therapy for the management of pubertal gynecomastia: a systematic review. *J Pediatr Endocr Met* 2013;26(9–10):803–7. <http://dx.doi.org/10.1515/jpem-2013-0052>.
- [9] Maidment SL. Question 2. Which medications effectively reduce pubertal gynaecomastia? *Arch Dis Child* 2010 Mar;95(3):237–9. <http://dx.doi.org/10.1136/adc.2009.176768>.